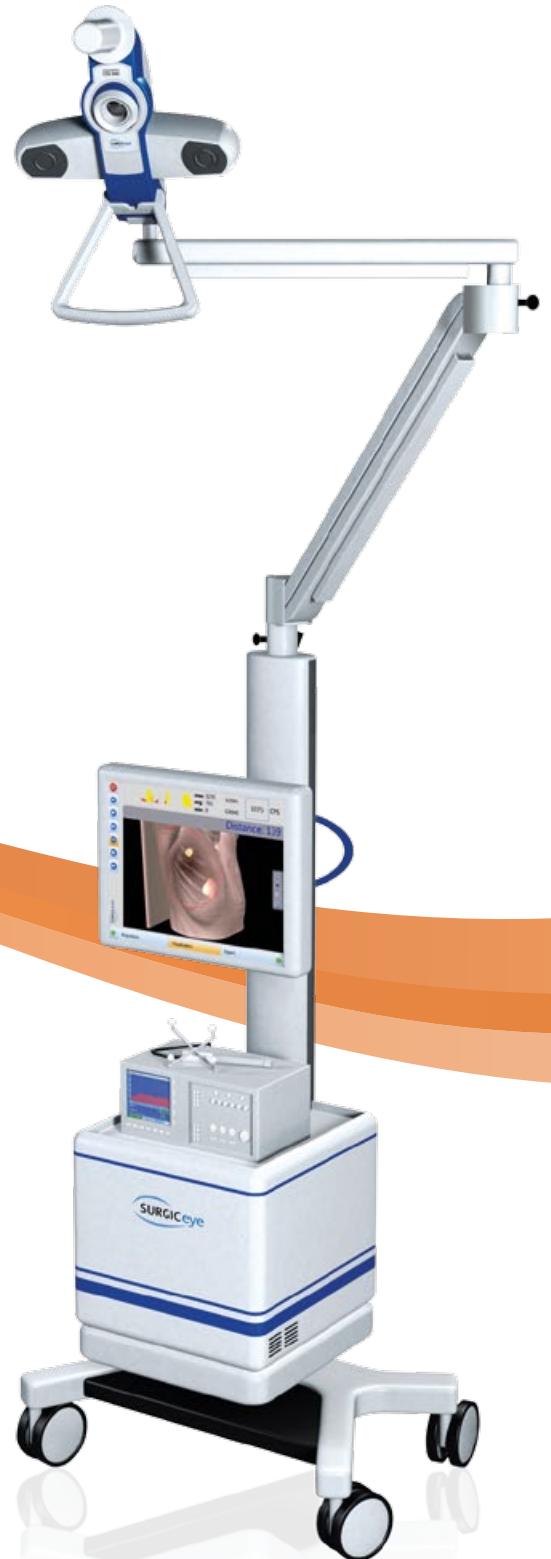








declipseSPECT

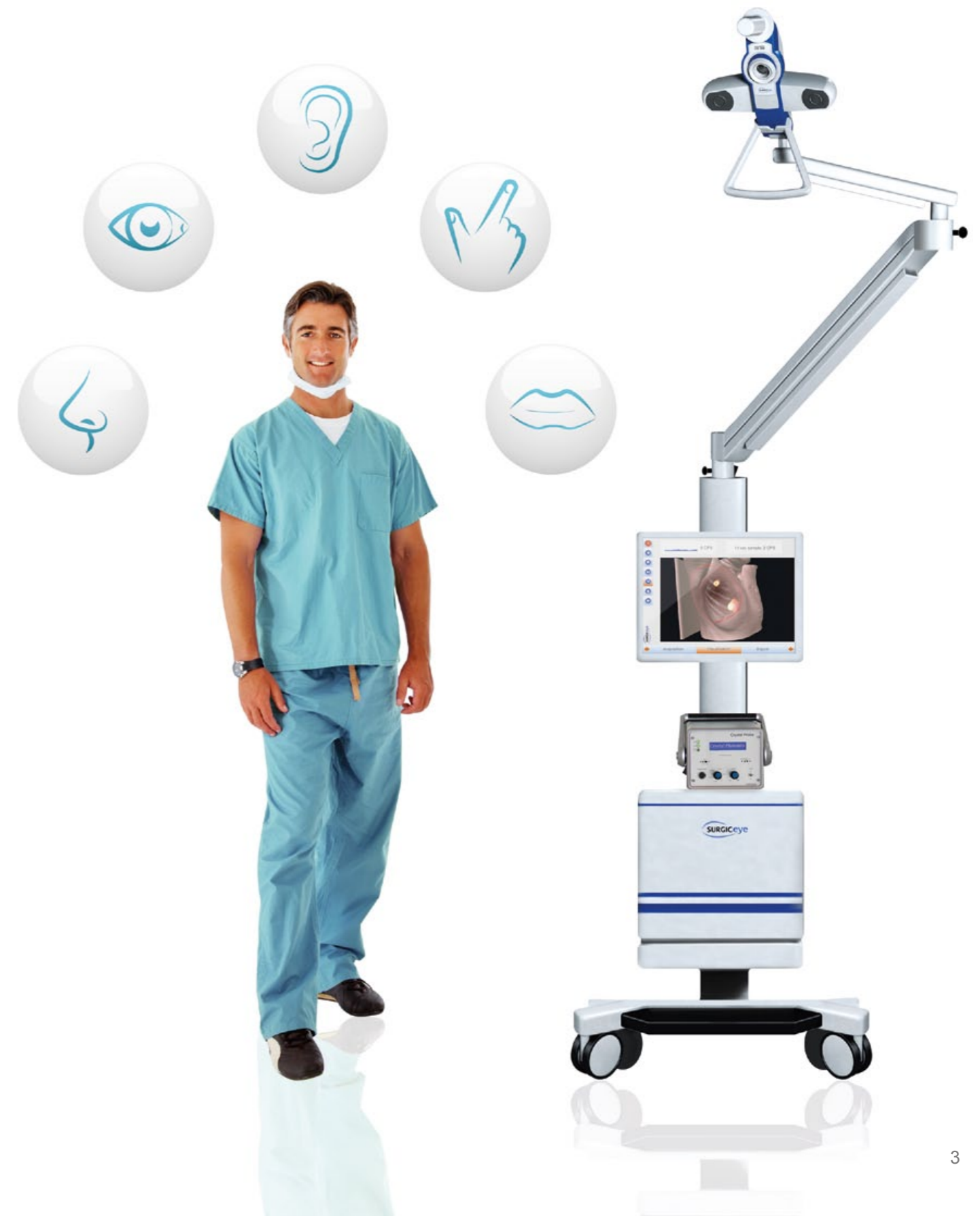Making the invisible visible

Rely on all your senses

Why use only isolated acoustic feedback, when you can visualize and navigate to your target?

Integrated radio-guided surgery solution **declipseSPECT**

-  **Navigation** - guidance for minimally invasive and assisted resection
-  **Visual feedback** - seeing the radioactivity within anatomical context
- High resolution** - vivid image quality for detailed anatomical visualization
- 3D** - for guidance and complete resection feedback in all dimensions
-  **Acoustic feedback** - seamless integration into current clinical workflow procedure
-  **Intraoperative** - generating and seeing the information when it is needed
- Depth information** - knowing how deep to go for direct access
- Labeling of radioactivity** - activity concentration in target to support decision making
- Flexible device** - optimal adaptation to your environment
-  **Communication** - digital data interface for collaborative challenges
- Documentation** - video and picture documentation



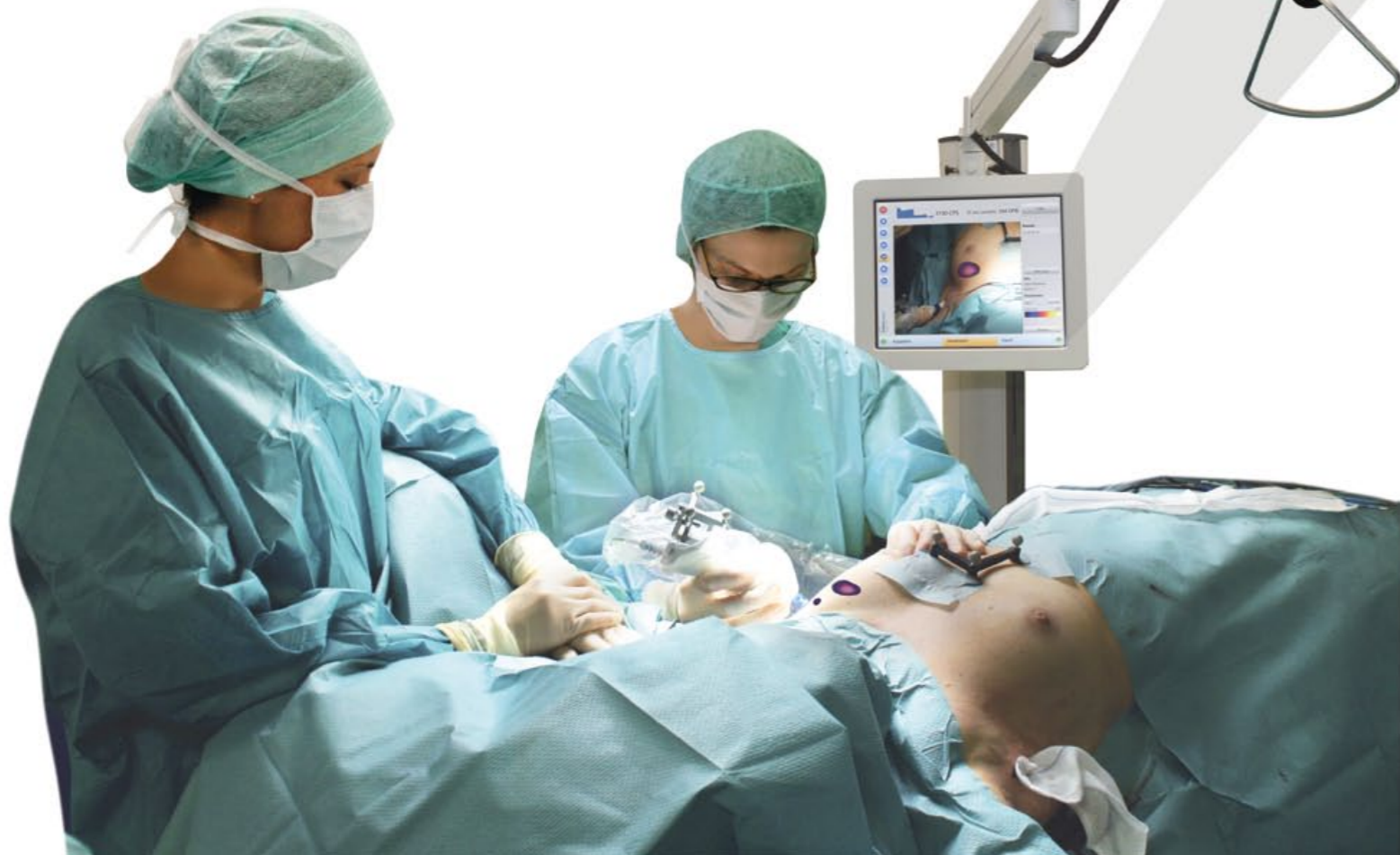declipseSPECT workflow

Are you interested in a “one-stop” procedure?

“The innovative 3D declipseSPECT technology may make the sentinel node biopsy easier and more reliable. New technologies like 3D declipseSPECT will also open up lymphatic mapping to additional cancer types, cancer types in locations with a more intricate anatomy and cancer types with more complex lymph drainage.”

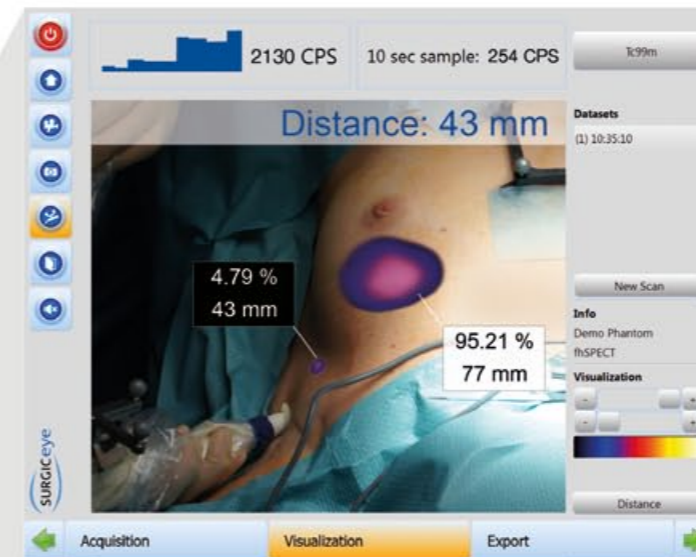Dr. Omgo E. Nieweg

Surgeon, The Netherlands Cancer Institute
Amsterdam, the Netherlands



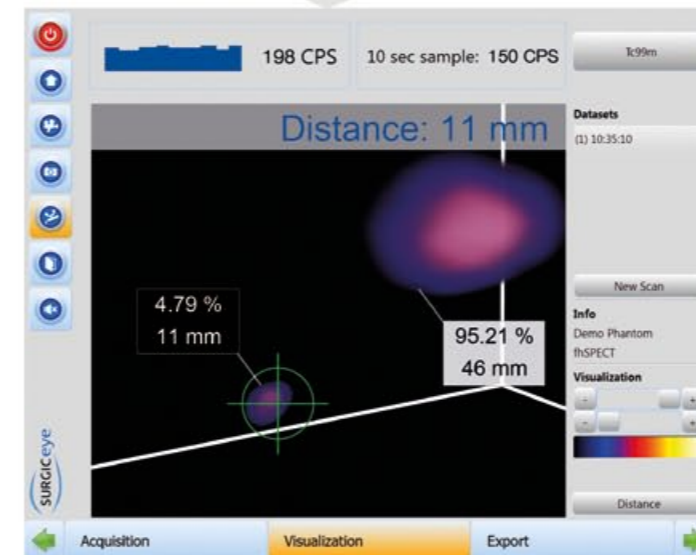
Easy set-up:

1. **Positioning** - Place the system where it does not interfere your work - ideally opposite to the operation site.
2. **Scanning** - Scan an area of 15x15 cm² around the expected location of the SLN and the tumor.



Enjoy visualization options:

3. **In situ visualization of 3D image fusion** - Activate the handy labels to visualize the radioactivity concentration on the impalpable primary tumor and the radioactive lymph nodes on the patient's body surface. This supports to determine the most radioactive sentinel lymph nodes. The image overlay in the operating room allows planning of an optimal surgical access and provides guidance for minimally invasive removal.



4. **3D visualization and labeling** - Change the image viewing to 3D. The Navigation to the radioactively marked primary tumors and sentinel lymph nodes is guided by the declipseSPECT 3D image. Direct access including depth measurements to the radioactive structures are shown. The radioactivity concentration labels help to identify the most important structures and highlight them. In case of a primary marked tumor this helps to confirm negative resection margins or guide the extension of the tumor bed.

Guidance during procedure:

5. **Resecting** - Navigate to the identified structures for minimally invasive surgery.
6. **Confirming** - Confirm the complete removal of radioactive structures.
7. **Documenting** - Document the procedure with video and images and generate standardized protocols.

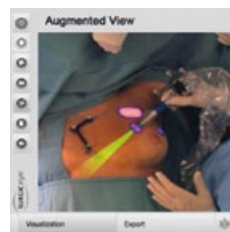declipseSPECT Applications

In which the declipseSPECT could help you?

"The declipseSPECT technology and its intraoperative use for navigated sentinel lymph node dissection enables safer surgeries, and less invasive procedures. This can ensure a high quality outcome for every individual patient."

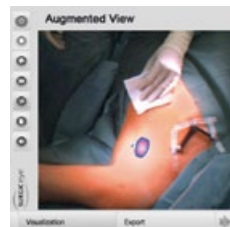Prof. Dr. Marion Kiechle

Director of the Women's Hospital Klinikum rechts der Isar
Munich, Germany



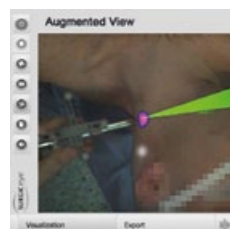
Sentinel Lymph Node Biopsy (SLNB) in Breast Cancer

declipseSPECT allows anytime during surgery a 3D image overview to guide proper and precise resection of sentinel lymph nodes. For quality assurance the system can document that all sentinel lymph nodes have been successfully removed¹.



Sentinel Lymph Node Biopsy (SLNB) Melanoma

Precise identification and localization of sentinel lymph nodes in 3D supports image-guided incision and resection. This proposes faster and minimally invasive surgeries².



Sentinel Lymph Node Biopsy (SLNB) in Head & Neck Cancer

The fusion of SPECT/CT data and the declipseSPECT technology used intraoperatively provides depths measurements and guidance for sentinel lymph node localization in head and neck malignancies³.

1. A. Schnelzer, A. Ehlerting, J. Ettl, T. Wendler, A. Buck, S. Paepke, M. Kiechle; Using freehand SPECT for 3D navigated radio-guided axillary sentinel lymph node biopsy and quality assurance in breast cancer surgery; Proceedings of the Annual San Antonio Breast Cancer Symposium (SABCC) 2010, San Antonio, Texas, USA, December 2010

2. S. Naji, A. Tadros, J. Traub, C. Healy; Case report: Improving the speed and accuracy of melanoma sentinel node biopsy with 3D intra-operative imaging; Journal of plastic, reconstructive & aesthetic surgery : JPRAS 1 December 2011 (volume 64 issue 12 Pages 1712-1715 DOI: 10.1016/j.bjps.2011.05.011)

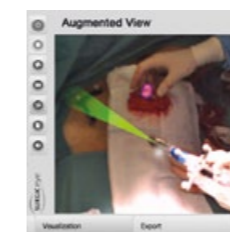3. T. Wendler, K. Scheidhauer, D. Zäuner, S. Wiesner; Fused SPECT/CT and real-time video visualization for intraoperative guidance in SLNB of head and neck malignancies; Proceedings of the International Sentinel Node Society Meeting, Yokohama, Japan, 2010

Further applications of radio-guided surgery

"The 3D declipseSPECT presents a potential tool in refining the excision margins of tumor in the ROLL technique. The possibility to observe the harvested tissue and the tracer activity within it offers a realistic view of the surgical procedure appropriateness in the operating room."

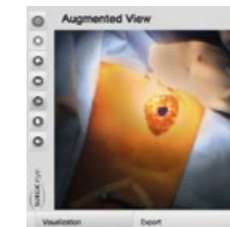
Dr. Sergi Vidal Sicart

Nuclear Medicine Specialist, Hospital Clínic
Barcelona, Spain



Radio-guided Occult Lesion Localization (ROLL) in Breast Cancer

Intraoperative imaging enables in addition to in-vivo 3D imaging, also ex-vivo examination directly after resection. Thus proposes boundary control through direct visual image overlay of Tc99 marked primary tumors.



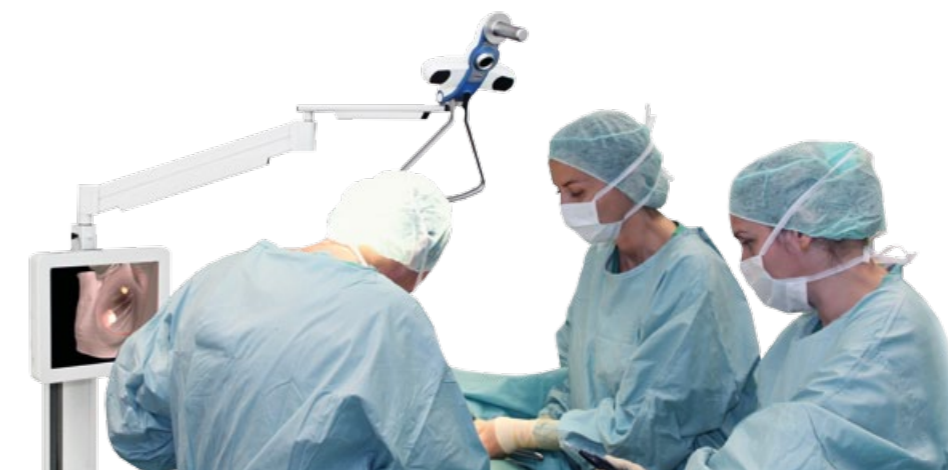Radio-guided Seed Localization (RSL) in Breast Cancer

Radioactive I125 seeds, the 3D image, and the depth information provided by the declipseSPECT help to define optimal incision and facilitate intuitive access to impalpable tumors.

• O. Brouwer, J. van der Hage; Initial experience with 3D intraoperative freehand SPECT probe imaging for radioguided tumor excision and sentinel node biopsy in breast cancer; European Molecular Imaging Meeting (EMIM), Leiden, the Netherlands 2011.

• R. J. Gray, R. Giuliano, E. L. Dauway, C. E. Cox, D. S. Reintgen; Radioguidance for nonpalpable primary lesions and sentinel lymph node(s); American journal of surgery 1 October 2001 (volume 182 issue 4 Pages 404-406)

• H. S. J. Ramesh, S. Anguille, L. S. Chagla, O. Harris, S. Desmond, R. Thind, R. A. Audisio; Recurrence after ROLL lumpectomy for invasive breast cancer; The Breast (December 2008), 17 (6), pg. 637-639





Vision for Tomorrow's Surgery

declipseSPECT

is developed and manufactured
in Munich, Germany
by **SurgicEye GmbH**
www.surgiceye.com

SurgicEye and **declipse** are registered
trademarks of **SurgicEye GmbH** in the EU

SurgicEye GmbH

Friedenstrasse 18a
81671 Munich
Germany
info@surgiceye.com
Phone +49 89 549 9890 00
Fax +49 89 549 9890 90